




The scoliosis of Richard III, last Plantagenet King of England: diagnosis and clinical significance

Jo Appleby, Piers D Mitchell, Claire Robinson, Alison Brough, Guy Rutty, Russell A Harris, David Thompson, Bruno Morgan



Neil Hall/Reuters/Corbis

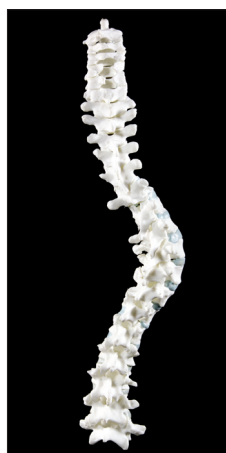Lancet 2014; 383: 1944

School of Archaeology and Ancient History (J Appleby PhD), East Midlands Forensic Pathology Unit (A Brough MSc, G Rutty MD), and Department of Radiology, University of Leicester (B Morgan PhD); Division of Biological Anthropology, University of Cambridge (P D Mitchell PhD); Imaging Department, University Hospitals of Leicester (C Robinson MSc); Wolfson School of Mechanical & Manufacturing Engineering, Loughborough University, UK (R A Harris PhD, D Thompson MSc)

Correspondence to: Dr Jo Appleby, School of Archaeology and Ancient History, University of Leicester, Leicester, LE1 7RH, UK ja253@leicester.ac.uk

See Online for appendix

See Online for videos and podcast



3D model of spine with replica polymer vertebrae created by laser sintering

Richard III was king of England from 1483 to 1485, after declaring his nephew, Edward V, illegitimate. On Aug 20, 1485, Richard was killed in battle with the rebel Lancastrian claimant Henry Tudor at Bosworth. His body was carried back to Leicester and buried in the Greyfriars Minor Friary, where it remained until its excavation in 2012, when it was seen to have a severe scoliosis.¹

Famously, Shakespeare described Richard III as “hunchbacked” in his eponymous play of 1593. There has been considerable disagreement whether this “hunchback” was real or an invention of his enemies after death, with political motivations. However, the chronicler John Rous wrote around 1490 that Richard “was small of stature, with a short face and unequal shoulders, the right higher and the left lower.”² This description is compatible with the presence of a right-sided scoliosis.

We analysed the skeleton macroscopically for evidence of spinal curvature and related lesions. From CT 3D reconstructions of each bone, we created polymer replicas and built a model of the spine to recreate its alignment in life (figure, appendix).

The apex of the right-sided thoracic curve noted at excavation was at vertebrae T8–T9. The Cobb angle,³ determined from vertical excavation photos, was 75° from the upper border of T6 to the lower border of T11. Since this was measured supine, whereas clinical angles are taken standing, we estimate the Cobb angle to have been in the range 70–90° during life. The curve was well balanced, with cervical and lumbar spines reasonably well aligned (King Moe type 3).⁴ Abnormalities of individual vertebrae (eg, wedging of vertebral end plates, lateral angulation of spinous processes, asymmetry of facet joints) were restricted to the thoracic region (appendix). The foramen magnum was normal in size and shape. The 3D reconstruction closely matches the 2D images recorded at excavation, and shows the spiral nature of the scoliosis (appendix, video).

Determining the cause of Richard’s scoliosis allows us to estimate the age at which it developed, and how it may have affected him. Since the spinal ligaments are some of the last to decompose after death, and in this case had partly ossified, the position of the vertebrae should show only minimum change from the time of burial, having been surrounded by soil. Such small change is supported by the similarity to the reconstructed model, which relied on joint morphology to determine each joint position. The absence of structural spinal abnormalities, such as hemivertebrae and unilateral bars, makes congenital scoliosis improbable. Neuromuscular causes, such as cerebral palsy, are unlikely because of the normal

structure, muscle markings, and cortical thickness of the legs and hips, compatible with a normal weight-bearing gait. Skeletal changes associated with syndromes such as Marfan’s (eg, high arched palate and tall stature) were not present, and a normal foramen magnum makes a Chiari malformation unlikely. The subtle nature of the changes in vertebral anatomy suggest onset in the last few years of growth, which is compatible with adolescent onset idiopathic scoliosis, probably starting after 10 years of age.

The physical disfigurement from Richard’s scoliosis was probably slight since he had a well balanced curve. His trunk would have been short relative to the length of his limbs, and his right shoulder a little higher than the left. However, a good tailor and custom-made armour could have minimised the visual impact of this. A curve of 70–90° would not have caused impaired exercise tolerance from reduced lung capacity,⁵ and we identified no evidence that Richard would have walked with an overt limp, because the leg bones are symmetric and well formed.

Contributors

JA excavated the skeleton, analysed the skeletal remains, and wrote much of the paper. PDM analysed the remains, classified and interpreted the scoliosis, and wrote part of the paper. CR supervised the CT scanning process. AB did 3D reconstructions of bone CT in preparation for 3D models and assisted with interpretation of CT. GR assisted with interpretation of CT and 3D models. RAH and DT provided the required electronic thresholding and data translation, and created the polymer replicas using a laser sintering 3D printing technique. BM planned and interpreted the CT imaging, made the 3D reconstruction model, and commented on the paper.

Acknowledgments

The original search for Richard III project which led to the discovery was jointly funded by the Richard III Society (especial thanks to Philippa Langley), Leicester City Council, and University of Leicester. The research for this paper was funded by the University of Leicester. The authors would like to thank Loughborough University for 3D models and the University Hospitals Leicester imaging department for use of the CT scanner. Photographs were taken by Carl Vivian of the University of Leicester.

References

- 1 Buckley R, Morris M, Appleby J, King T, O’Sullivan D, Foxhall L. “The king in the car park”: new light on the death and burial of Richard III in the Grey Friars church, Leicester, in 1485. *Antiquity* 2013; **87**: 519–38.
- 2 Rous J. *Joannis Rossi Antiquarii Warwicensis Historia Regum Angliae*. Oxford: J Fletcher & J Pote, 1745 [1486].
- 3 Cobb RJ. Outline for the study of scoliosis. In: *American Academy of Orthopaedic Surgeons Instructional Course Lectures*. Ann Arbor: J W Edwards, 1948. **5**: 261–75.
- 4 King HA, Moe JH, Bradford DS, Winter RB. The selection of fusion levels in thoracic idiopathic scoliosis. *J Bone Joint Surg Am* 1983; **66**: 1061–71.
- 5 Weinstein SL, Dolan LA, Spratt KF, et al. Health and function of patients with untreated idiopathic scoliosis: a 50-year natural history study. *JAMA* 2003; **289**: 559–67.